

Scrub Typhus with Acute Respiratory Distress Syndrome (ARDS) and its Management in Intensive Care Unit: A Case Report

SRINIVAS SANKURATRI¹, PAVANI KALAGARA², KARTIKA BALAJI SAMALA³, PRABHAKAR KRISHNA VELEDANDI⁴, SRINADH BABU ATIKETI⁵

ABSTRACT

Scrub typhus is zoonotic disease caused by *Orientia tsutsugamushi* (*O tsutsugamushi*). It is transmitted to humans by the bite of trombiculid mite larvae (chiggers). It is a re-emerging infectious disease in India. Clinical manifestations include fever, headache, anorexia, myalgia, eschar, adenopathy and maculopapular rash. Complications of Scrub typhus develop after first week of illness. Complications include meningoencephalitis, jaundice, myocarditis, ARDS and renal failure. Eschar and rash may be unnoticed or absent. Thorough physical examination, identification of eschar/rash throws light in thinking about scrub typhus, treating and preventing further complications. Here, we report a case of scrub typhus with Acute Respiratory Distress Syndrome (ARDS) and its management with non invasive ventilation in the intensive care unit.

Keywords: Eschar, Non-invasive positive pressure ventilation, Weil-Felix test, Zoonotic

CASE REPORT

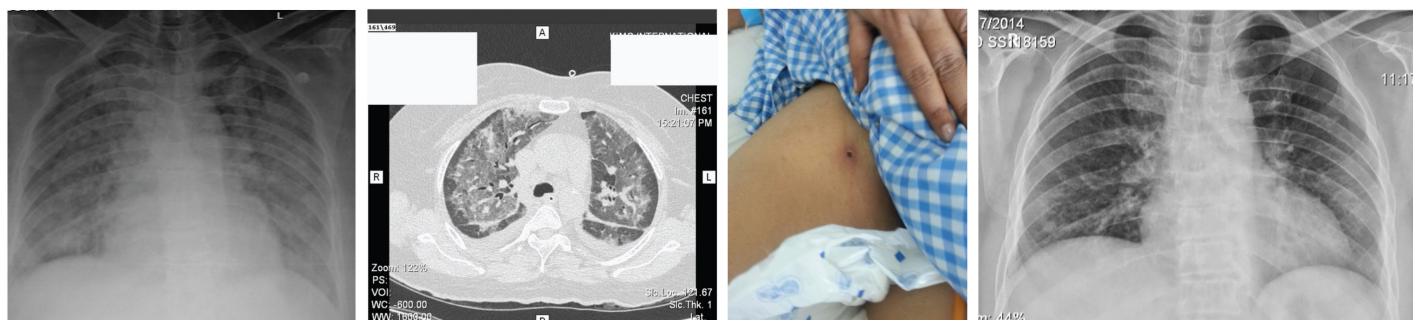
A 52-year-old female was referred to emergency department of Krishna Institute of Medical Sciences, Hyderabad, India with complaints of fever with chills and rigours, cough with expectoration and grade III-IV shortness of breath since one week. She didn't have any significant past medical, surgical or family history of illness. She was agricultural worker from South India. She was on in-patient treatment for five days in a local hospital with no relief from symptoms. Because of persistent fever and cough as well as radiological evidence of bilateral pneumonia, she was referred to Krishna Institute of Medical Sciences as a case of bilateral pneumonia.

Informed consent has been taken from the patient and attendants. On admission at the intensive care unit (ICU), the patient had fever, chills, cough, shortness of breath and lethargy. Her pulse rate was 134/min, a respiratory rate was 36/min, blood pressure was 100/70mmHg and temperature was 39°C. Respiratory system examination revealed bilateral decreased breath sounds with bilateral basal crepitations. Other systems were within normal limits. Arterial Blood gas analysis (ABG) revealed Type I respiratory failure. Patient required Non-invasive positive pressure ventilation for the first 4 days intermittently during her stay at ICU. 4-6 Litres of Oxygen with face mask was given to the patient during rest of the period. Blood was sent for investigations and empirical antibiotic treatment was started with intravenous Cefoperazone and Sulbactam (1.5 gram twice daily). Patient was nebulised with bronchodilators and chest

physiotherapy was done. Laboratory data revealed leukocytosis, thrombocytopenia, elevated aspartate aminotransferase, alanine aminotransferase and hypoalbuminemia. Smears for malarial parasite were negative. WIDAL, Leptospira and Dengue serology were negative. The blood and sputum samples were sent for culture. A chest radiograph and computerised tomography image of chest showed bilateral alveolar shadows consistent with acute respiratory distress syndrome (ARDS) and also consolidation [Table/Fig-1,2].

During a detailed general examination an eschar [Table/Fig-3] was observed in the right thigh region. Pathognomonic eschar being the most important clinical finding in scrub typhus infection, blood sample was sent for Weil Felix test. Empirical treatment with doxycycline was initiated. Weil-Felix test was positive (OX-K titre > 320). The blood and sputum culture were sterile. Presence of eschar, positive weil-felix test along with ruling out other febrile illnesses confirmed the diagnosis of scrub typhus. Final diagnosis of scrub typhus with ARDS was made. In view of confirmed Scrub typhus diagnosis, patient received oral doxycycline (100mg twice daily) for 10 days and intravenous Cefoperazone and Sulbactam (1.5 gram twice daily) for one week to control any other lung infection if present.

Week days later, her condition improved, she did not require any non-invasive ventilation and was shifted to the room from ICU. Patient was discharged from the hospital on 17-12-2014. Chest X-ray at the time of discharge revealed decreased alveolar shadows [Table/Fig-4].



[Table/Fig-1]: X-Ray Chest at the time of admission [Table/Fig-2]: CT-Scan Chest at the time of admission [Table/Fig-3]: Photograph showing eschar in the right thigh region [Table/Fig-4]: X-Ray chest at discharge

DISCUSSION

Scrub typhus is an acute febrile illness caused by gram negative bacterium *Orientia tsutsugamushi* (family Rickettsiaceae). It is endemic to a part of the world known as the "Tsutsugamushi triangle". In India, the disease is widely spread and reported in many states. It is transmitted to humans by bite of larval stage (chigger) of trombiculid mites. Wild rats are the reservoirs for chiggers and infection occurs when chiggers feed on humans. Literature suggests risk of exposure is more among people living in rural areas, agricultural workers, soldiers. In our case report, patient is from rural background and an agricultural worker [1,2].

The clinical manifestations of this disease range from fever, headache, non-productive cough and eschar to fatal complications like pneumonitis, encephalitis and peripheral circulatory failure. A necrotic eschar at the wound site is most important diagnostic clue to scrub typhus [3]. Late presentation, delay in diagnosis and drug resistance are the main reasons for the death [3]. Vivekanandan M et al., studied over a period of two years and diagnosed scrub typhus based on eschar and positive weil felix test with a titre > 1:80 [4]. Acute respiratory distress syndrome (ARDS) is a serious complication of scrub typhus and pulmonary manifestations vary from bronchitis, interstitial pneumonitis progressing to ARDS [5]. Wang CC et al., did an extensive study on ARDS in patients with scrub typhus. The mortality rate was around 25% and timely intervention with Doxycycline or Chloramphenicol decreased it [6].

A study by Varghese GM et al., included 623 patients admitted between 2005 and 2010 where common presenting symptoms were fever, nausea/vomiting, shortness of breath, headache, cough and altered sensorium. Scrub typhus is underdiagnosed due to its non specific presentation like lack of eschar in 40-60% of cases. An eschar was present in almost 50% of cases. Laboratory findings usually are elevated transaminases, thrombocytopenia and leukocytosis which were typically seen in our patient [7]. The specificity and positive predictive value for diagnosis of scrub typhus is 80% if elevated transaminases, thrombocytopenia and leukocytosis are present in a patient [8]. Several studies have shown that Weil Felix test has high specificity. Weil Felix agglutination test is specific when positive with titres >320 [9,10]. In our patient, pathognomic eschar with positive weil felix test (>320), occupational history made us to diagnose scrub typhus.

Scrub typhus formed >15% of cases with suspected diagnosis of tropical fevers admitted in ICU in the data presented at annual conference of Indian Society of Critical Care Medicine (ISCCM) in 2014 by them [11]. Thirty seven percent of scrub typhus patients with hypoxemia required mechanical ventilation, 15.55 % required non invasive ventilation [11]. Our patient didn't have the necessity of invasive ventilation and was comfortable, improved well with non invasive positive pressure ventilation. Patients with malaria followed by scrub typhus and ARDS, renal failure together showed high mortality. Encephalopathy was an independent predictor of mortality [11].

CONCLUSION

We are reporting this case to highlight the need for thorough history taking, clinical examination, awareness of manifestations of scrub typhus like ARDS, renal failure, sometimes multiorgan dysfunction. Non-invasive positive pressure ventilation was helpful in successful outcome and the necessity of invasive ventilation wasn't seen in our patient.

REFERENCES

- [1] Hornick BB. Rickettsial diseases. In: Bennett JC, Plum F, editors. Goldman: Cecil Textbook of Medicine. 21st ed. Philadelphia, USA: WB Saunders Company; 2000.pp.1911-12.
- [2] Narvekar KP, Rodrigues S, Narvekar RP, et al. Scrub typhus in patients reporting with acute febrile illness at a tertiary health care institution in Goa. *Indian J Med Res.* 2012;136:1020-24.
- [3] Mahajan SK. Scrub typhus. *J Assoc Physicians India.* 2005;53:954-58.
- [4] Vivekanandan M, Mani A, Priya YS, Singh AP, Jayakumar S, Purty S. Outbreak of scrub typhus in Pondicherry. *J Assoc Physicians India.* 2010;58:24-28.
- [5] Chayakul P, Panich V, Silpapojakul K. Scrub typhus pneumonitis: an entity which is frequently missed. *Q J Med.* 1998;68:595-602.
- [6] Wang CC, Liu SF, Liu JW, Chung YH, Su MC, Lin MC. Acute respiratory distress syndrome in scrub typhus. *Am J Trop Med Hyg.* 2007;76:1148-52.
- [7] Varghese GM, Trowbridge P, Janardhanan J, Thomas K, Peter JV, Mathews P, et al. Clinical profile and improving mortality trend of scrub typhus in south india. *Int J Inf Dis.* 2014;23:39-43.
- [8] Chogle AR. Diagnosis and treatment of scrub typhus – the Indian scenario. *J Assoc Physicians India.* 2010;58:11-12.
- [9] Brown GW, Shirai A, Rogers C, Groves MG. Diagnostic criteria for scrub typhus probability values for immunofluorescent antibody and proteus OXK agglutinin titres. *Am J Trop Med Hyg.* 1983;32(5):1101-07.
- [10] Prakash JA, Abraham OC, Mathai E. Evaluation of tests for serological diagnosis of scrub typhus. *Trop Doct.* 2006;36:212-13.
- [11] Rungta N. Scrub typhus: Emerging cause of multiorgan dysfunction. *Indian J Crit Care Med.* 2014;18:489-91.

PARTICULARS OF CONTRIBUTORS:

1. Senior Consultant, Department of Critical Care, Medical ICU, Krishna Institute of Medical Sciences Hospitals, Secunderabad, India.
2. Assistant Professor, Department of Microbiology, Apollo Institute of Medical Sciences & Research, Jubilee Hills, Hyderabad, India.
3. Junior Consultant, Department of Critical Care, Medical ICU, Krishna Institute of Medical Sciences Hospitals, Secunderabad, India.
4. Junior Consultant, Department of Critical Care, Medical ICU, Krishna Institute of Medical Sciences Hospitals, Secunderabad, India.
5. Junior Consultant, Department of Critical Care, EMD, Krishna Institute of Medical Sciences Hospitals, Secunderabad, India.

NAME, ADDRESS, E-MAIL ID OF THE CORRESPONDING AUTHOR:

Dr. Kartika Balaji Samala,
Junior Consultant, Medical ICU, Krishna Institute of Medical Sciences, Secunderabad, Telangana, India.
E-mail : Kartik1414@gmail.com

FINANCIAL OR OTHER COMPETING INTERESTS: None.

Date of Submission: **Feb 24, 2015**
Date of Peer Review: **Apr 07, 2015**
Date of Acceptance: **Apr 17, 2015**
Date of Publishing: **May 01, 2015**